

SPINAL CORD AND NERVES VIDEO RECORDING LINKS

Dr. Lisa Brinn

Video Recording Links for Lecture

- [Module 12 LO1 Video Spinal Cord](#)
- [Module 12 L02 Video Spinal Nerves](#)
- [Module 12 L03 Video Reflexes](#)

Video Recording Links for Lab

- [Module 12 Video Lower Limb Nerves Plexus Model](#)
- [Module 12 Video Upper Limb Nerves Plexus model](#)
- [Module 12 Video Spinal Cord Structures](#)
- [Module 12 Video Upper Limb Nerves](#)
- [Module 12 Video Lower Limb Nerves](#)

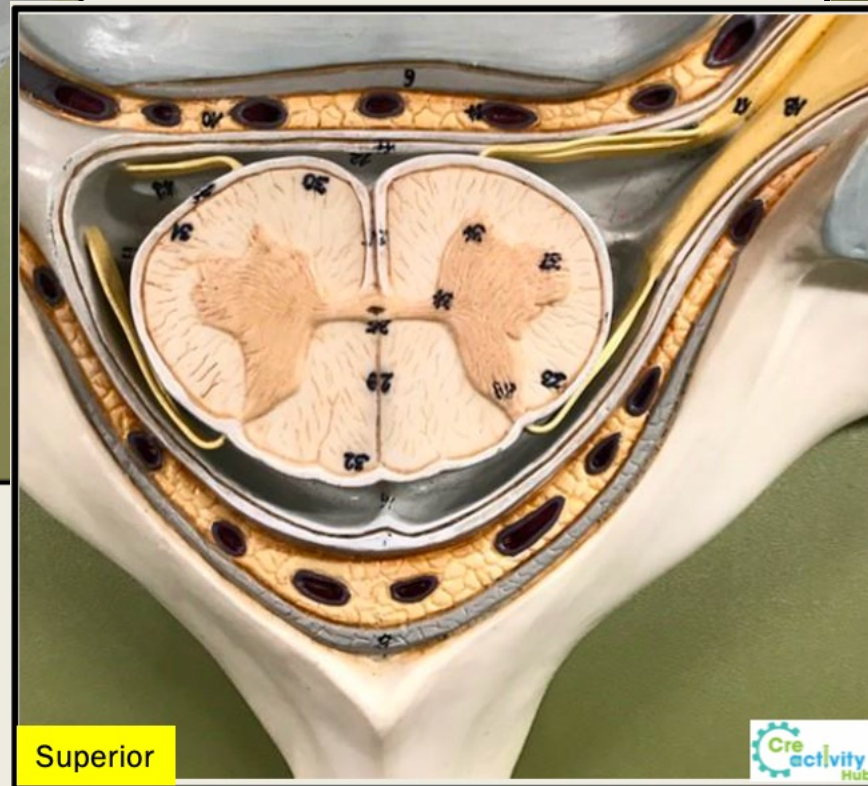
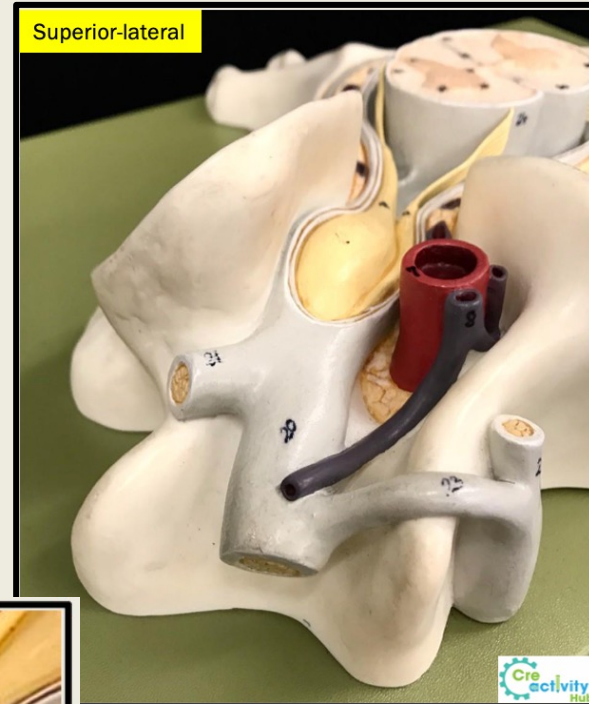
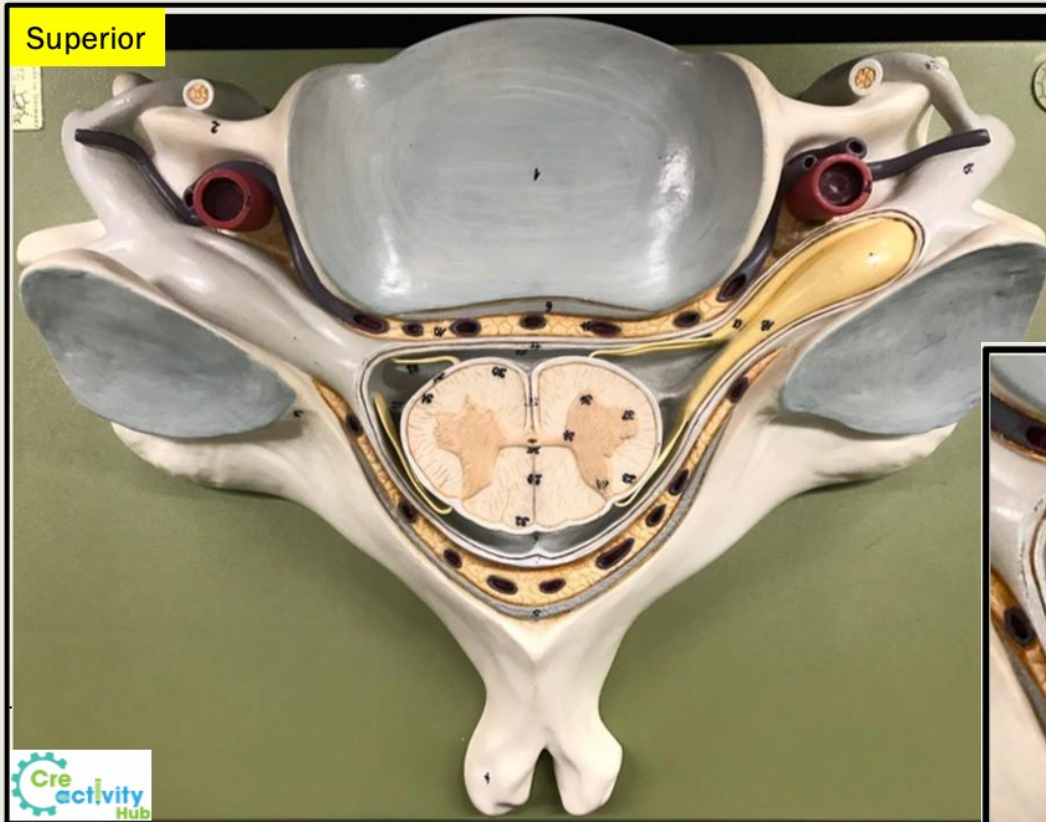Spinal Cord Model

meninges	spinal nerves	spinal cord
<ul style="list-style-type: none">• dura mater• subdural cavity• arachnoid mater• subarachnoid cavity• pia mater	<ul style="list-style-type: none">• ventral root• dorsal root• dorsal root ganglion• dorsal ramus• ventral ramus	<ul style="list-style-type: none">• denticulate ligaments• rami communicantes• sympathetic ganglion• white matter• gray matter• anterior median fissure• posterior median sulcus• central canal• posterior gray horn• lateral gray horn• anterior gray horn

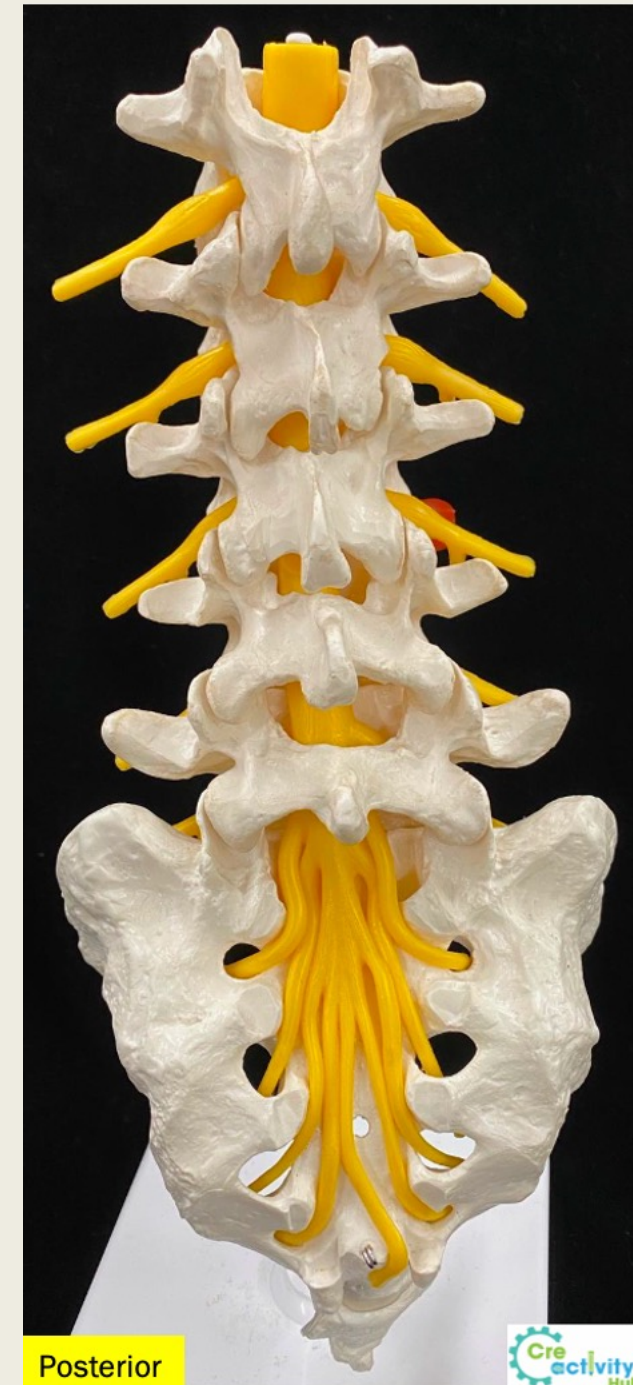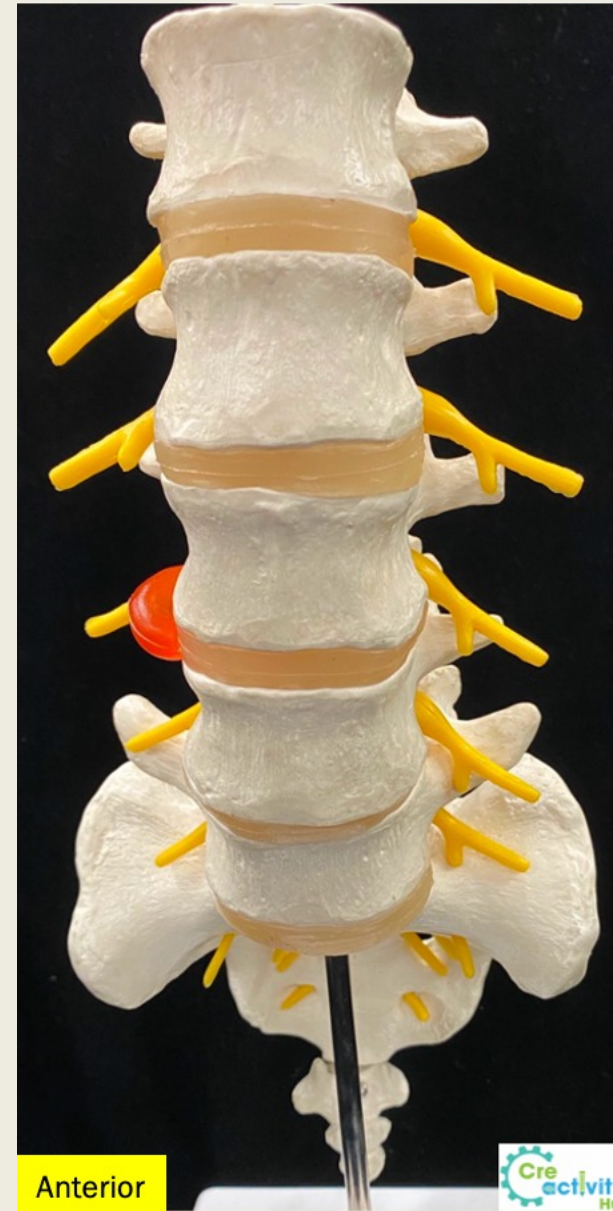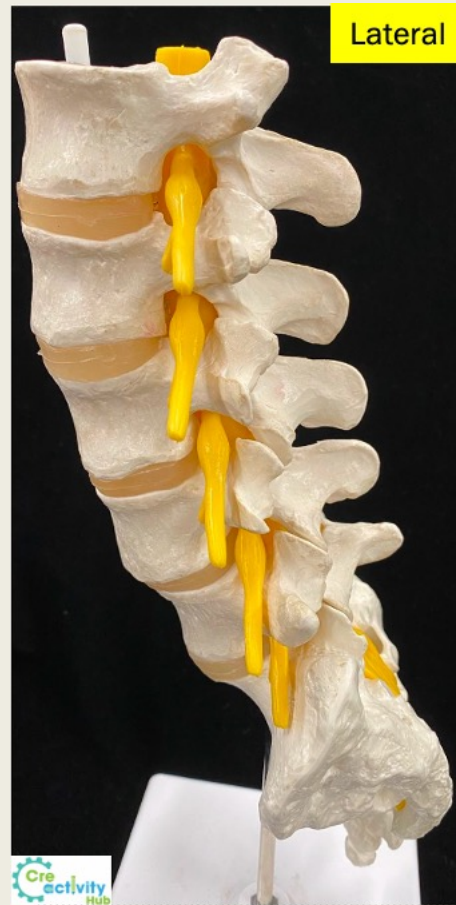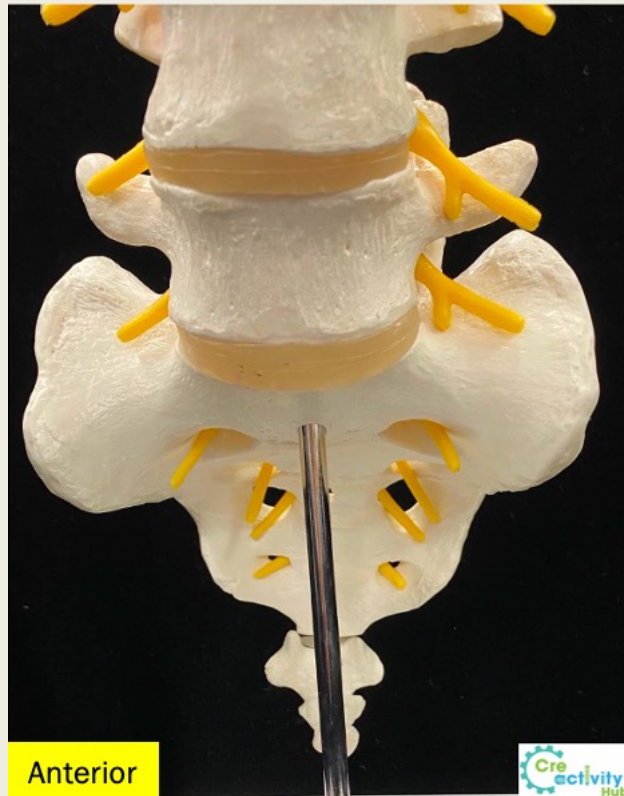
Spinal Nerves Plexuses

Cervical Plexus	Brachial Plexus	Lumbar and Sacral Plexuses
<ul style="list-style-type: none"> • phrenic nerve 	<p><i>Trunks:</i></p> <ul style="list-style-type: none"> • superior trunk • middle trunk • inferior trunk <p><i>Cords:</i></p> <ul style="list-style-type: none"> • lateral cord • posterior cord • medial cord <p><i>Nerves:</i></p> <ul style="list-style-type: none"> • ulnar nerve • radial nerve <ul style="list-style-type: none"> ○ deep radial nerve ○ superficial radial nerve • median nerve • musculocutaneous nerve • axillary nerve 	<p>Lumbar Plexus</p> <ul style="list-style-type: none"> • obturator nerve • femoral nerve <p>Sacral Plexus</p> <ul style="list-style-type: none"> • sciatic nerve • tibial nerve • common fibular nerve <ul style="list-style-type: none"> ○ superficial fibular nerve ○ deep fibular nerve <p>cauda equina conus medullaris</p>

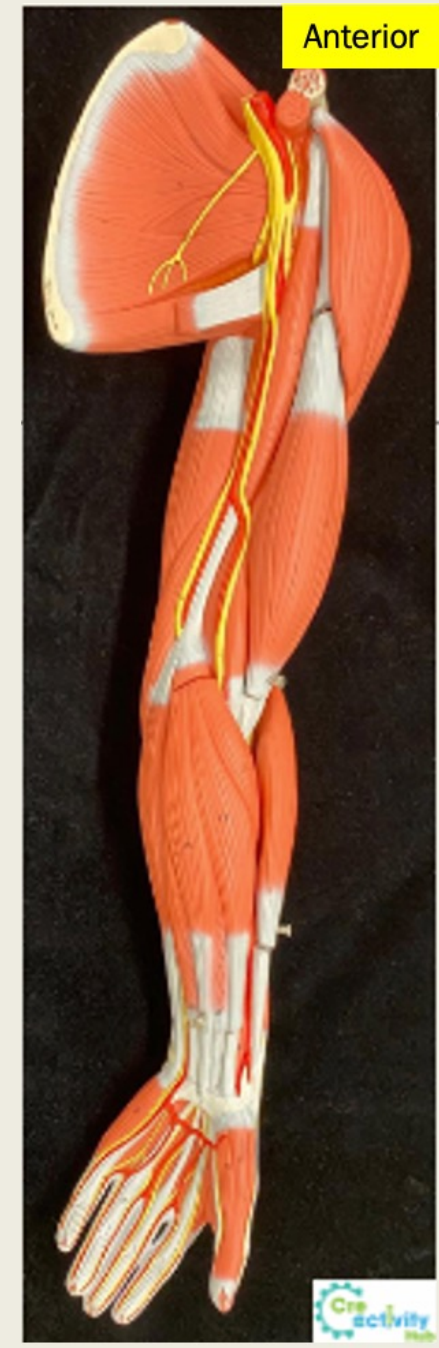
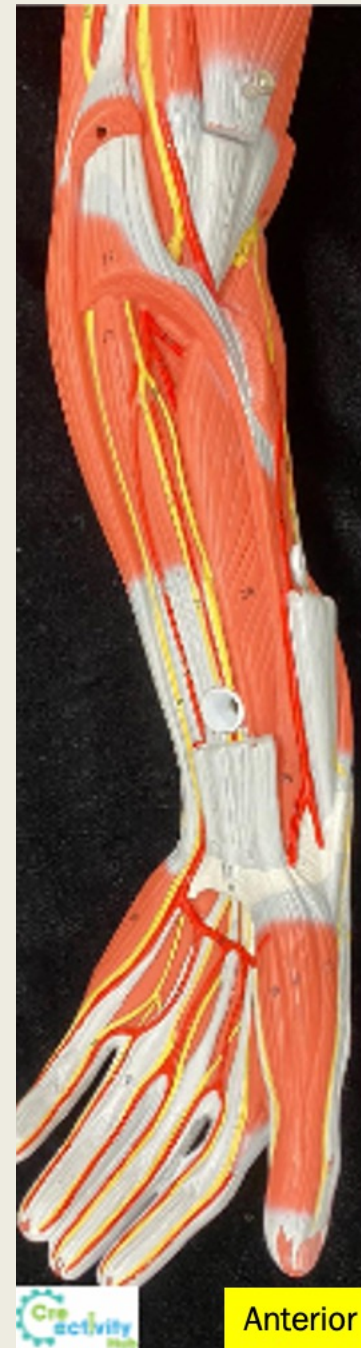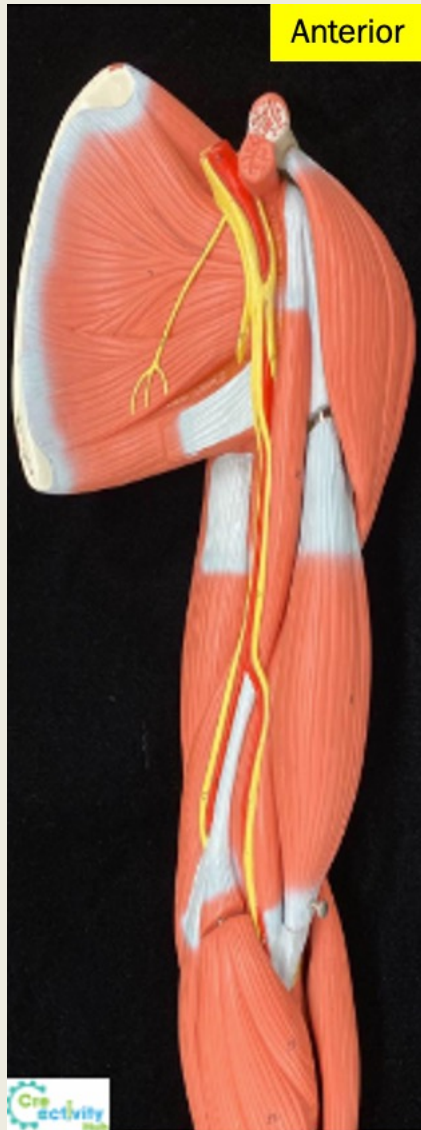Cervical Vertebra



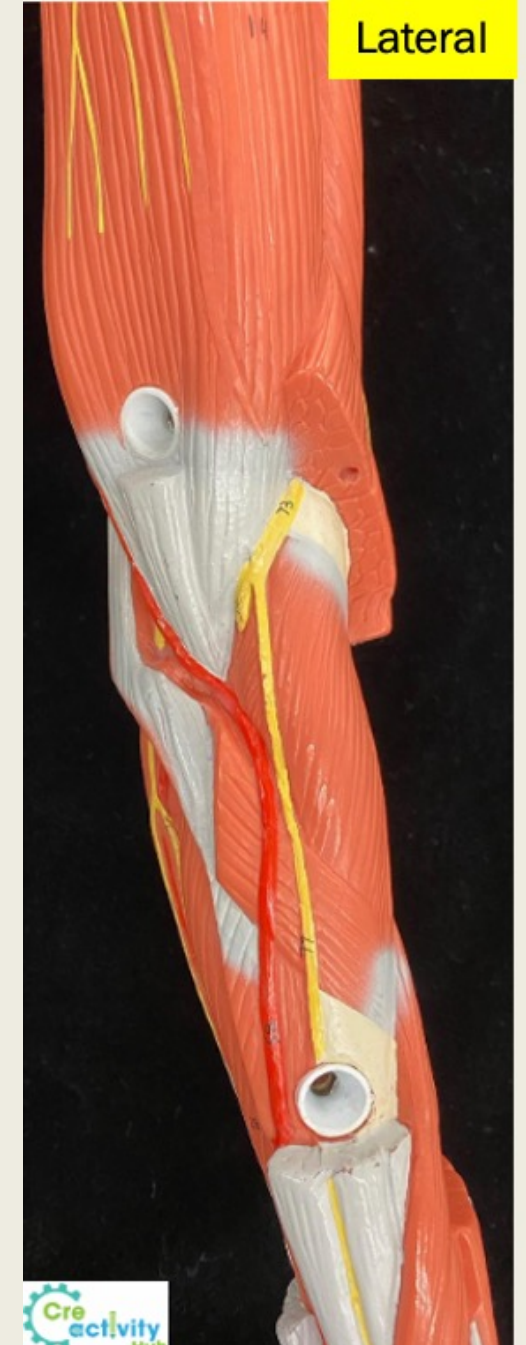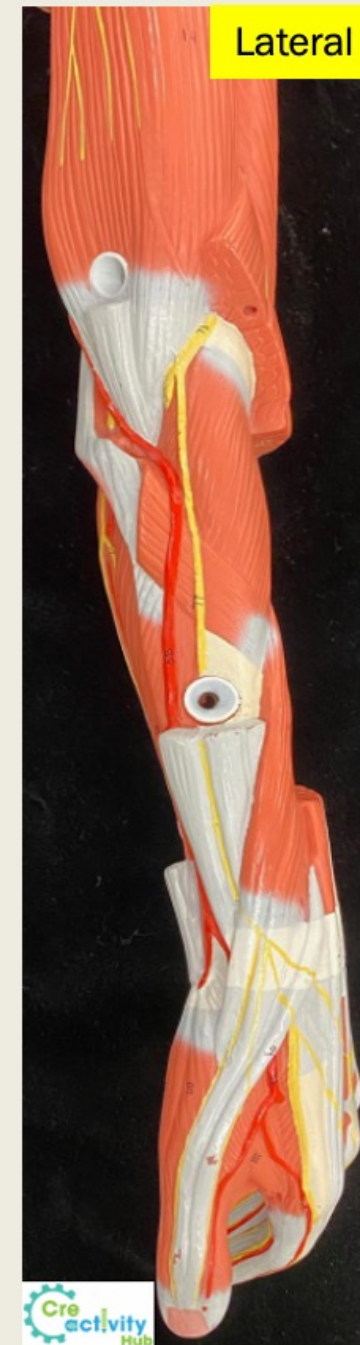
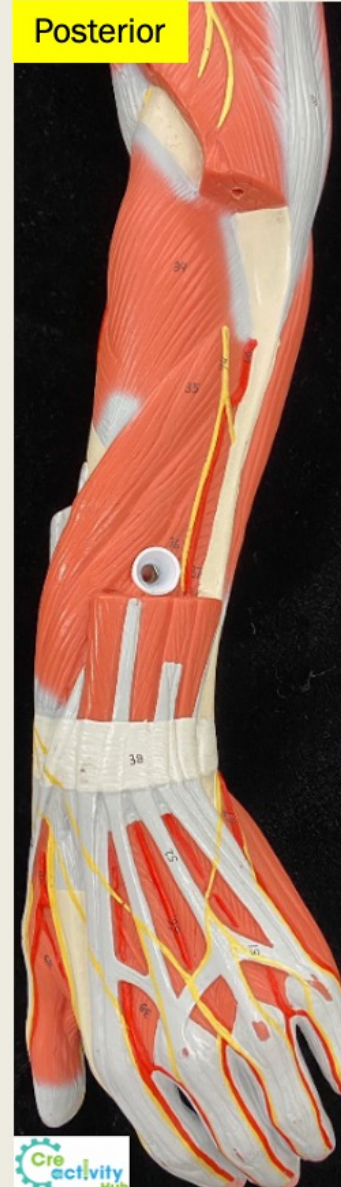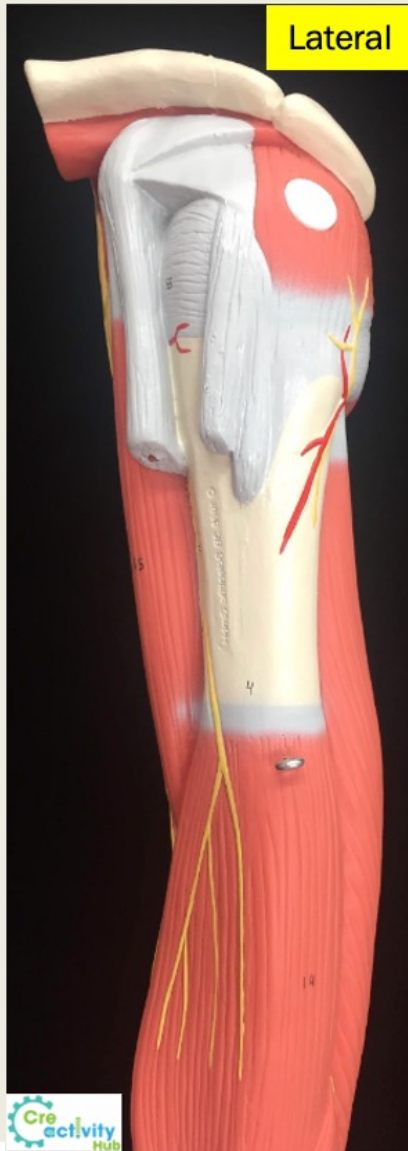
Lumbar and Sacral Region



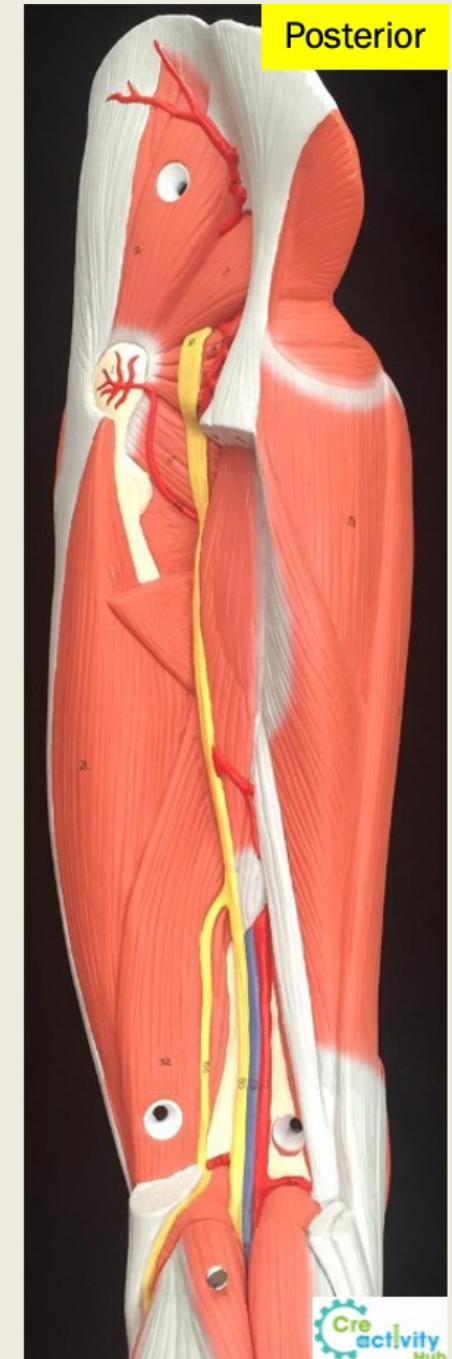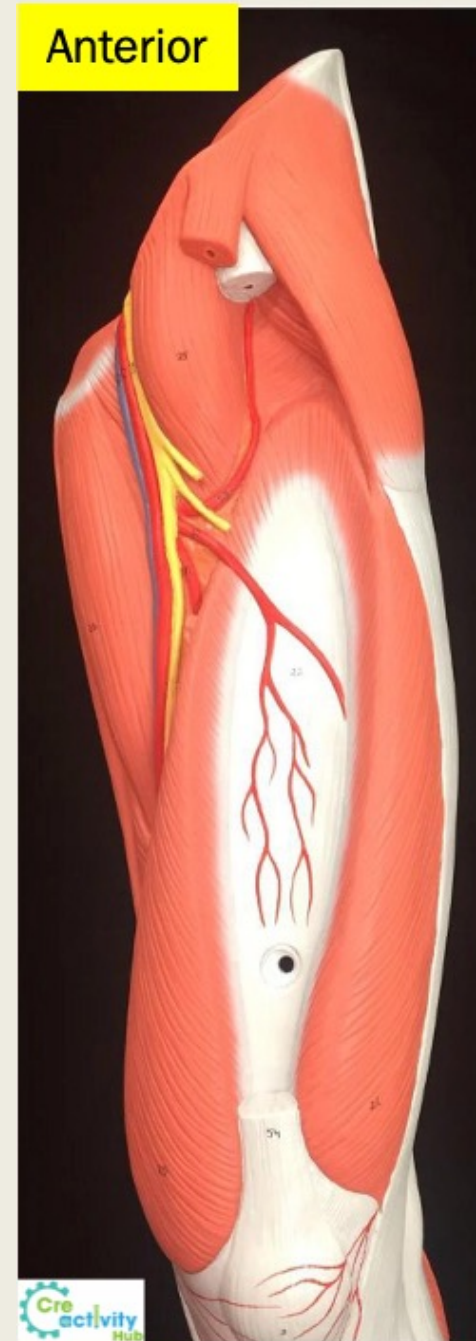
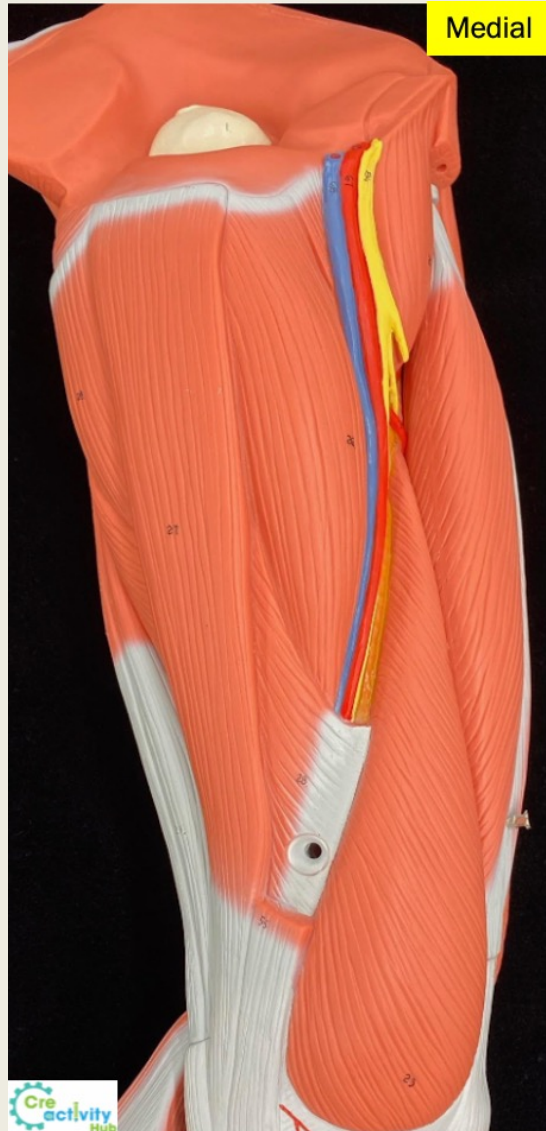Upper Limb Nerves



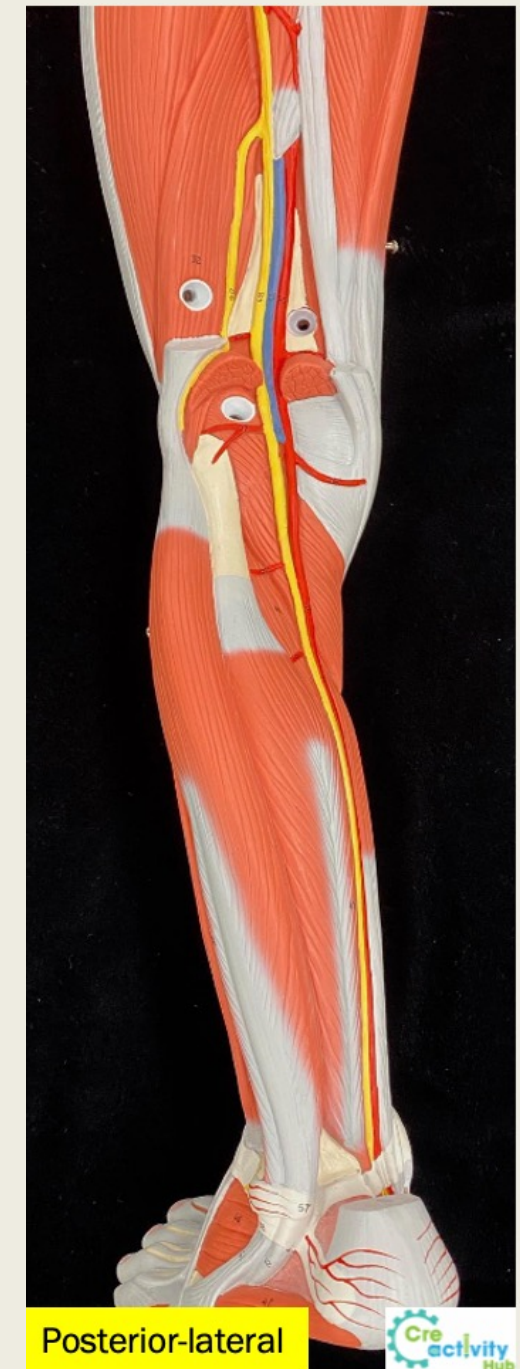
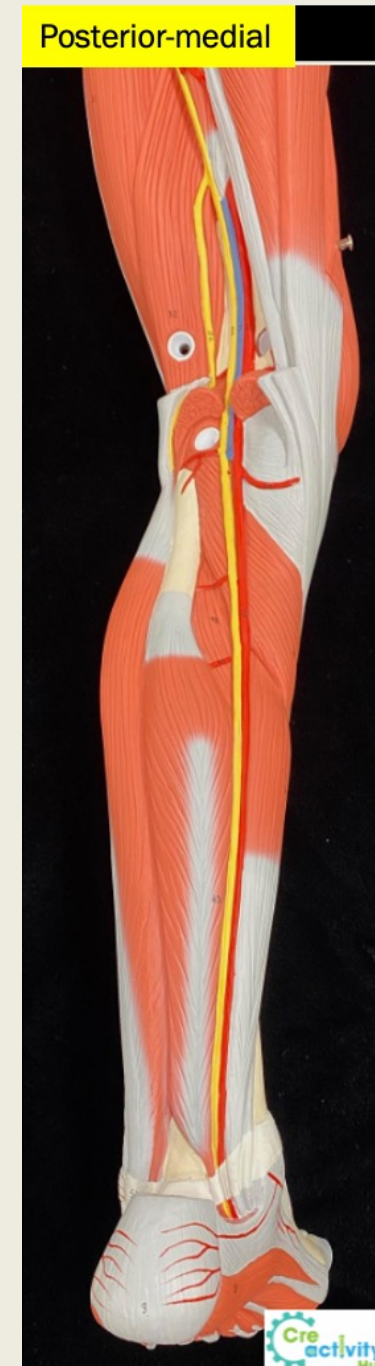
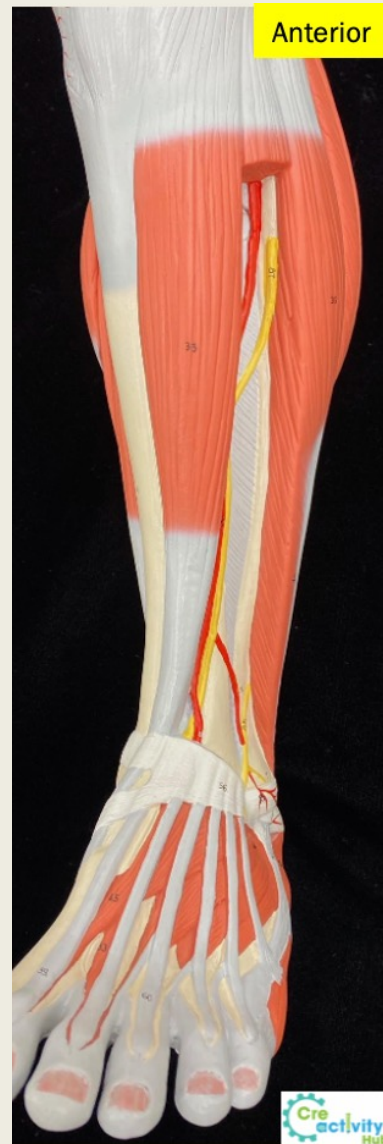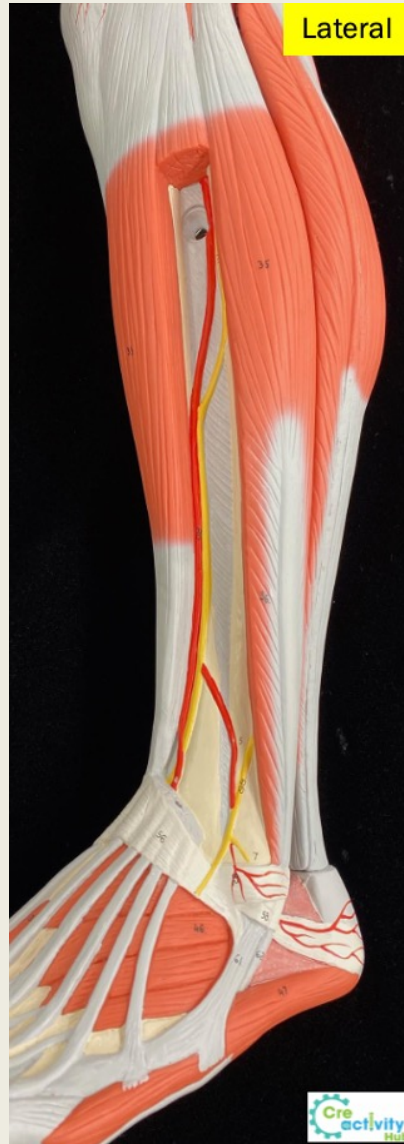Upper Limb Nerves



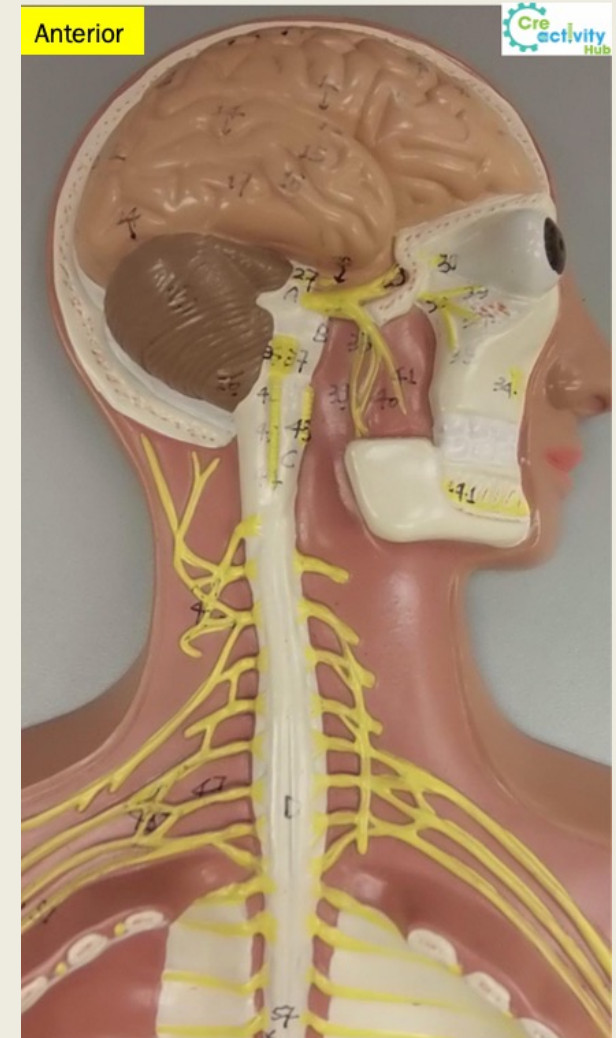
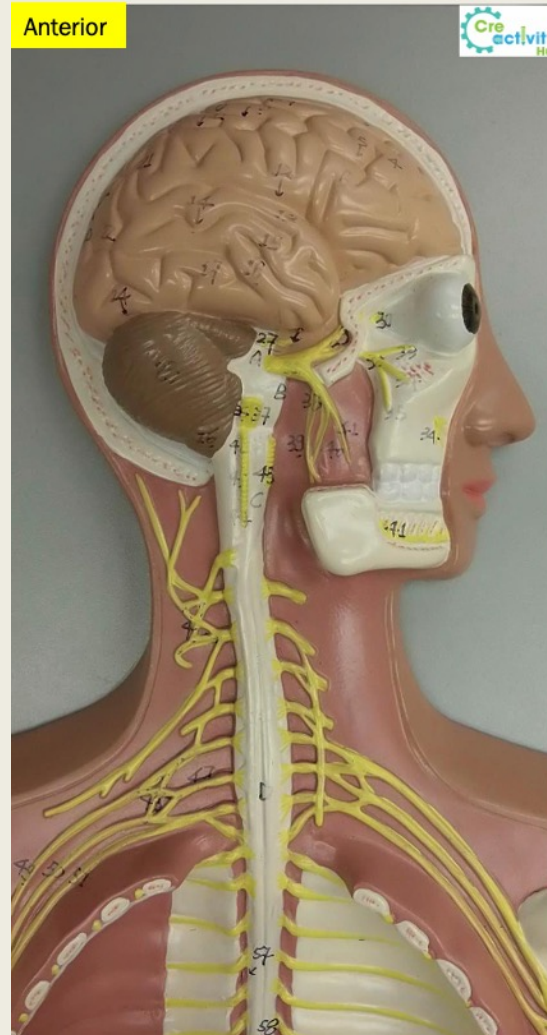
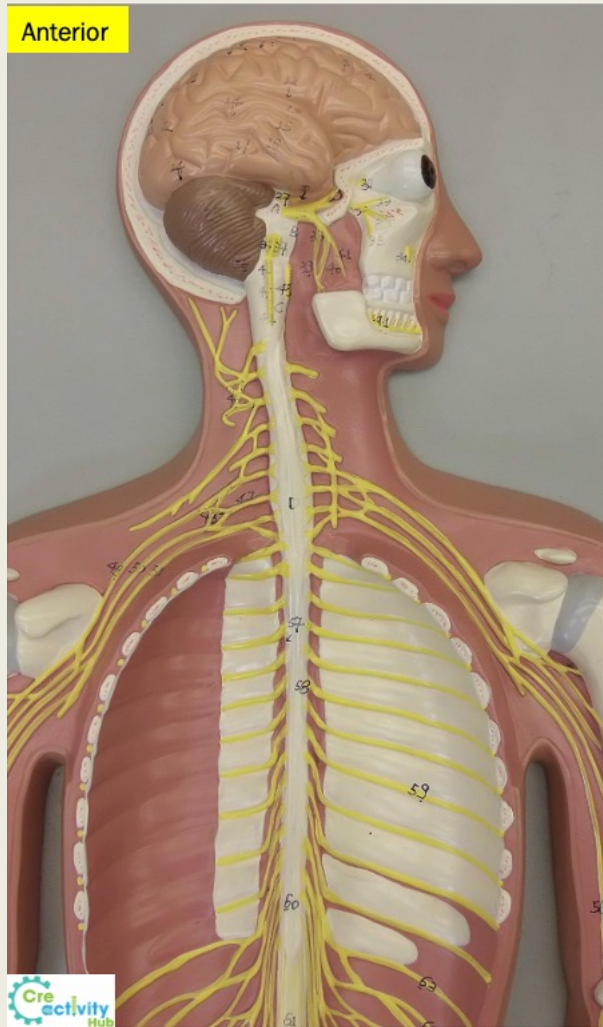
Lower Limb Nerves



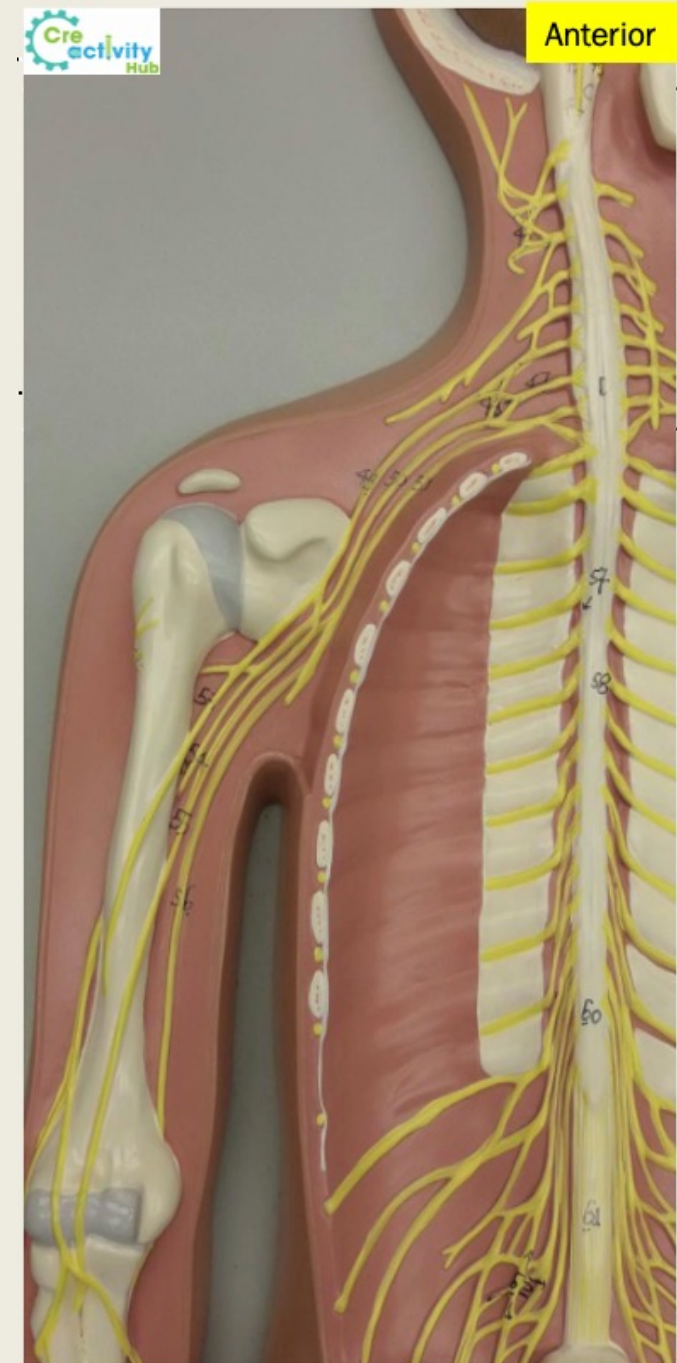
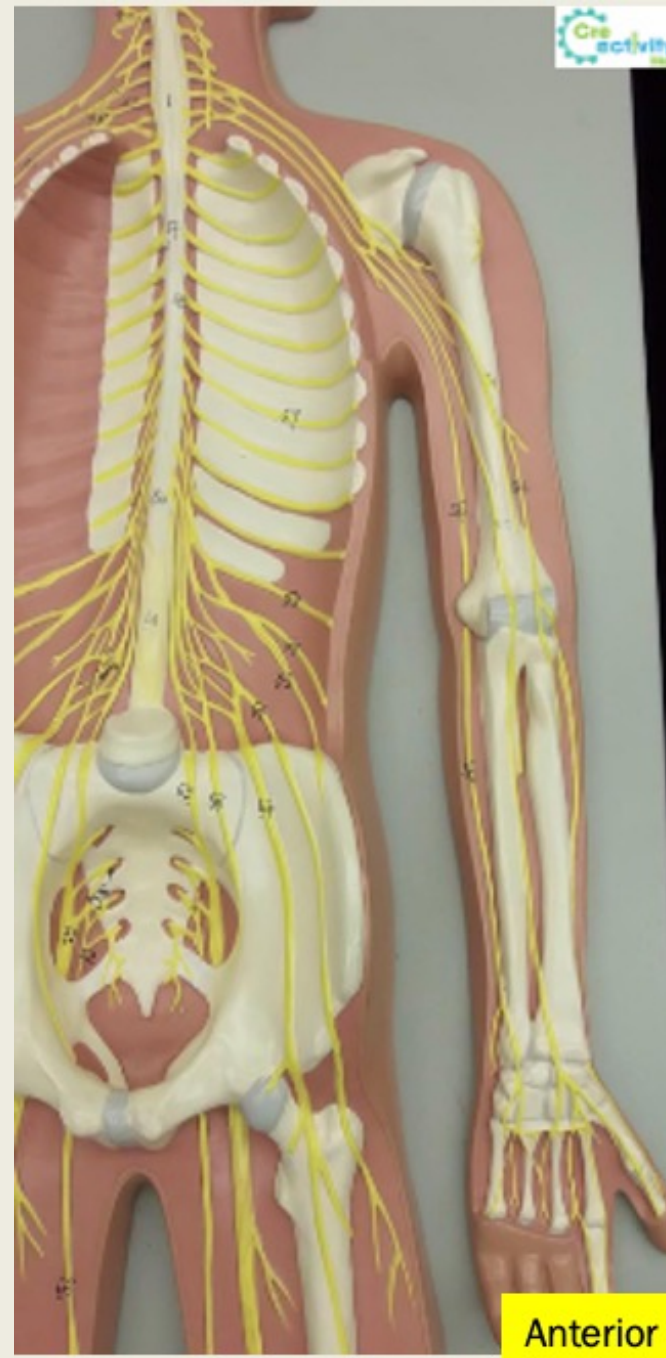
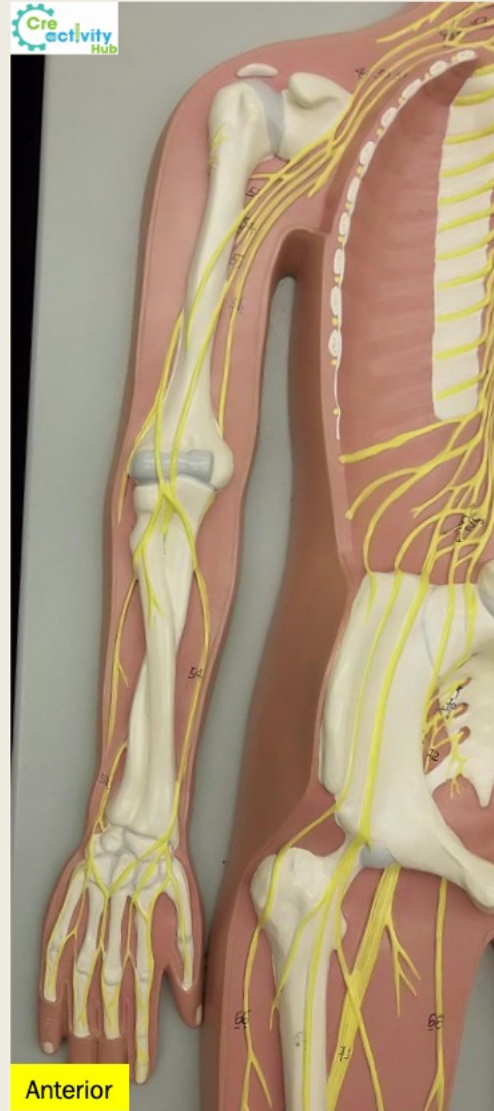
Lower Limb Nerves



Nerve Plexuses

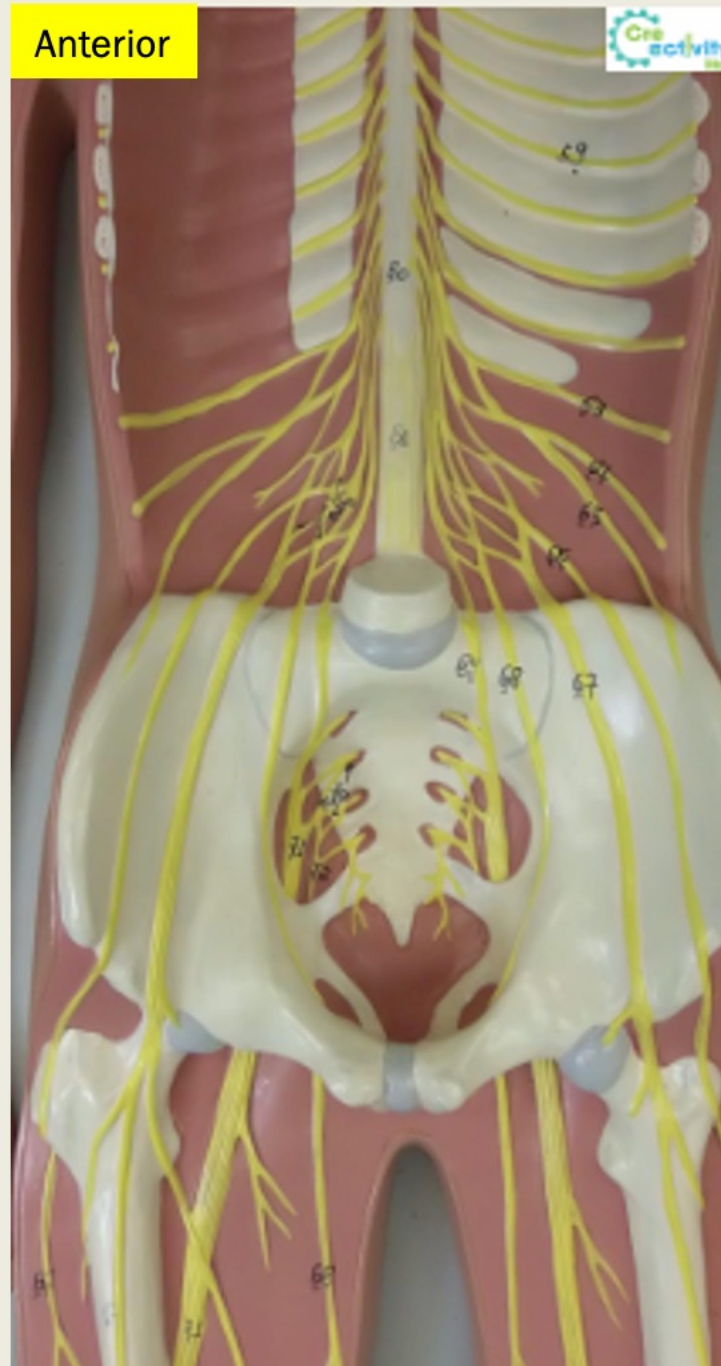

Nerve Plexuses



Nerve Plexuses

Anterior



Anterior

